

Widespread brain activity during an abdominal task markedly reduced after pain physiology education: fMRI evaluation of a single patient with chronic low back pain

G Lorimer Moseley

Department of Physiotherapy, Royal Brisbane and Women's Hospital and The University of Queensland, Brisbane

Scanning parameters Multislice gradient ECHO sequence:

- total scan time = 240 sec
- number of volumes = 80
- TR = 3 sec
- TE = 30 ms
- FOV = 256 mm²
- matrix = (64 x 64)

Preprocessing protocols The following pre-statistics processing was applied:

- motion correction
- non-brain removal
- spatial smoothing using a Gaussian kernel of FWHM 5 mm
- mean-based intensity normalisation of all volumes by the same factor
- high-pass temporal filtering (Gaussian-weighted LSF straight line fitting, with sigma = 20.0s).

Z (Gaussianised T/F) statistic images were thresholded using

clusters determined by $Z > 2.3$ and a (corrected) cluster significance threshold of $p = 0.01$, which was further corrected for multiple measures ($p < 0.005$).

Motion correction report Absolute (relative) mean displacements were 0.22 mm (0.12 mm), 0.21 mm (0.11 mm), and 0.22 mm (0.12 mm) for scans 1, 2, and 3 respectively.

Time series plot Figure A1 shows the time series plot of mean intensity for significant voxels between scans 2 and 3.

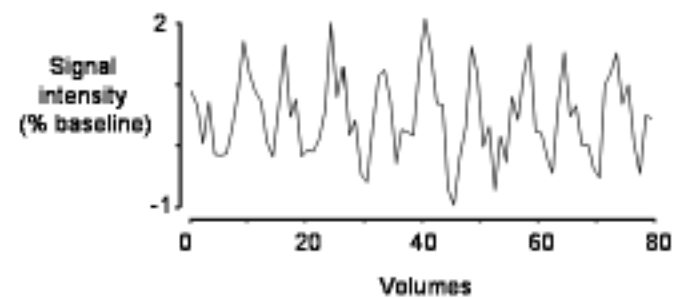


Figure A1. Time series plot.