

## Graded Motor Imagery and the Impact on Pain Processing in a Case of CRPS

Andrea D. Walz, MSc,\* Taras Usichenko, MD,† G. Lorimer Moseley, PhD,‡§ and Martin Lotze, MD\*

**Objective:** Graded motor imagery (GMI) shows promising results for patients with complex regional pain syndrome (CRPS).

**Methods:** In a case with chronic unilateral CRPS type I, we applied GMI for 6 weeks and recorded clinical parameters and cerebral activation using functional magnetic resonance imaging (fMRI; pre-GMI, after each GMI block, and after 6 mo). Changes in fMRI activity were mapped during movement execution in areas associated with pain processing. A healthy participant served as a control for habituation effects.

**Results:** Pain intensity decreased over the course of GMI, and relief was maintained at follow-up. fMRI during movement execution revealed marked changes in S1 and S2 (areas of discriminative pain processing), which seemed to be associated with pain reduction, but none in the anterior insula and the anterior cingulate cortex (areas of affective pain processing). After mental rotation training, the activation intensity of the posterior parietal cortex was reduced to one third.

**Discussion:** Our case report develops a design capable of differentiating cerebral changes associated with behavioral therapy of CRPS type I study.

**Key Words:** complex regional pain syndrome, training, fMRI, body matrix, neuropathic pain

(*Clin J Pain* 2013;29:276–279)

Complex regional pain syndrome (CRPS) affects 1% to 5% of patients after limb trauma<sup>1</sup> and leads to chronic pain associated with sensory, motor, and autonomic dysfunction in the affected limb.<sup>2</sup> Patients with CRPS have sensory disturbances that are not related to the edema; for example, disturbances of body ownership,<sup>3</sup> impression of increased size of the affected limb,<sup>4</sup> and perceptual deficits defined by the space in which the hand resides rather than the hand itself.<sup>5</sup> Imaging studies show that the cortical

representation of the affected hand in contralateral primary somatosensory cortex is smaller than that of the unaffected hand and of either hand in healthy controls.<sup>6</sup> This cortical reorganization is also associated with decreased tactile acuity.<sup>7</sup>

The treatment of CRPS using analgesic medication is still a major problem.<sup>8</sup> However, the substantial evidence of cortical contributions to CRPS has led to behavioral approaches that target the cortical representation of the affected limb. One promising approach is graded motor imagery (GMI).<sup>9</sup> We investigated the effect of GMI on the cortical representation of the affected limb in a patient with a 42-month history of CRPS type I using functional magnetic resonance imaging (fMRI). We predicted changes predominantly in areas associated with discriminative aspects of pain processing, as has been shown for other interventions.<sup>10</sup> In addition, because GMI involves complex mental rotation (MR) of one's own limbs, we predicted altered activation magnitude in the posterior parietal lobe (PPC), which has been shown to process complex MR.<sup>11</sup> We also tested for a possible contribution of the primary motor cortex (M1) in MR, as this is currently under debate.<sup>12</sup>

### MATERIALS AND METHODS

After providing informed consent, a mixed-handed, with a preference for the right hand (LQ<sup>13</sup> = 43), 37-year-old woman undertook a 6-week GMI<sup>9</sup> program and 5 fMRI investigations. The patient developed CRPS type I of her right hand 42 months ago after repeated surgery for tenosynovitis. The pain medication, using 300 mg opioid analgesic hydromorphone and 8 mg anticonvulsant gabapentin, was kept at constant dosage over the time of the study. An age-matched and sex-matched healthy control participant underwent the same scanning procedures without undertaking GMI. The local ethics committee approved the study.

The GMI program consisted of 3 sequential 2-week phases: (1) MR (making left/right judgments of pictured hands using the web-accessible software "Recognise"<sup>14</sup>); (2) movement imagery (imagined movements to match the posture of pictured hands, using "Recognise"<sup>14</sup>); and (3) mirror movements (performing movements with the intact hand while observing it in a mirror to arouse the impression of the affected hand moving likewise). Each GMI phase was divided into several parts with specific contents to increase the training load. One single trial lasted 5 to 10 minutes and should be carried out at each awake hour. The training is fully described by Moseley.<sup>9</sup>

The patient rated her at-rest and movement-evoked pain (the patient clenched and unclenched her fist 4 to 5 times consecutively) on a visual analogue scale (10 cm) before therapy, before each fMRI investigation, with a pain

Received for publication February 11, 2011; revised January 12, 2012; accepted February 17, 2012.

From the \*Functional Imaging, Institute for Diagnostic Radiology and Neuroradiology; †Department of Anesthesiology and Intensive Care Medicine, Ernst Moritz Arndt University of Greifswald, Greifswald, Germany; ‡Sansom Institute for Health Research, University of South Australia, Adelaide, SA; and §Neuroscience Research Australia, Sydney, NSW, Australia.

Supported by a grant from the DFG (LO 795/10-1). G.L.M. is supported by the National Health & Medical Research Council of Australia (ID 571090). The authors declare no conflict of interest.

Reprints: Martin Lotze, MD, Functional Imaging Unit, Center for Diagnostic Radiology and Neuroradiology, University of Greifswald, Friedrich-Löffler-Straße 23a, D-17487 Greifswald, Germany (e-mail: martin.lotze@uni-greifswald.de).

Supplemental Digital Content is available for this article. Direct URL citations appear in the printed text and are provided in the HTML and PDF versions of this article on the journal's Website, www.clinicalpain.com.

Copyright © 2012 by Lippincott Williams & Wilkins

diary during therapy twice daily, and retrospectively for the follow-up period (Fig. 1A). For additional data we collected, see Supplementary Methods. fMRI was carried out 5 times: pre-GMI, after phase 1, phase 2, and phase 3 (post-GMI) of GMI, and at the 6-month follow-up. We tested motor execution (ME) and MR.

For ME, a standardized dynamic isometric hand-grip task was performed with target rate 0.5 Hz and target force 33% maximum voluntary contraction (MVC) as measured at pre-GMI. Before each scanning session, the task was performed until the participant controlled it reliably. During fMRI measurement, the required rate of hand grip was indicated visually by a circle displayed at the center of the screen. The hand-grip rate and the amplitude of grip force were recorded using a pneumatic rubber ball system (details see Gustin et al<sup>10</sup>). ME was carried out once with the intact and once with the affected hand. We used a blocked design, consisting of 5 blocks' rest alternating with 4 blocks' task performance.

For MR, left/right hand judgments had to be delivered for approximately 24 photos of hands presented in a pseudorandomized counterbalanced order. The participant had to decide whether she saw a left or a right hand by pressing with the left unaffected hand the respective button on a pad (MR suitable keypads with physiologically ordered buttons of 1.5 cm in diameter connected through an optic fiber cable to a recording computer outside the scanner room) when the query appeared on the screen. The condition was performed in an event-related design consisting of 24 events for MR performance. Each of these events lasted 6 seconds and was followed by the response with a duration of 2 seconds and an ensuing rest period of 8 seconds (fixation cross). The 3 conditions (ME affected, ME unaffected, and MR) were presented in a pseudorandomized counterbalanced order.

Magnetic resonance imaging (3T Magnetom Verio, Siemens, Erlangen, Germany) was performed with a 32-channel head using conventional sequence parameters for echo planar imaging and high-resolution T1-weighted anatomic images (further information see Supplementary Methods, Supplemental Digital Content 1, <http://links.lww.com/CJP/A41>). Data analysis was performed using the statistical parametric mapping software (SPM8, Wellcome Department for Imaging Neuroscience) using standard settings (for further information see Supplementary Methods, Supplemental Digital Content 1, <http://links.lww.com/CJP/A41>). Regions of interest (ROIs) were selected from results of other studies (see Introduction section). For ME, these ROIs were the anterior insula and the anterior cingulate cortex (ACC) as areas associated with affective pain processing, and the primary somatosensory cortex (S1) and the secondary somatosensory cortex (S2) as areas associated with discriminative pain processing. For MR, M1 and the posterior parietal lobule were selected. The intensity of activation within ROIs' highest activated voxel during premeasurement was plotted over time for the patient (Fig. 1).

## RESULTS

### Pain Evaluation

Before therapy, the patient rated the intensity of her movement-evoked pain at 9.4 cm and her spontaneous pain at rest at 8.5 cm on the visual analogue scale. The pain decreased over the course of GMI to <1 cm (Fig. 1A), and

relief was maintained at the 6-month follow-up at a level <5 cm [pre-GMI–post-GMI pain at rest ( $t(7) = 2.16$ ;  $P < 0.05$  for all, one sided] and movement-evoked pain [ $t(7) = 1.98$ ;  $P < 0.05$  for all, one sided, Fig. 1A].

### fMRI

#### ME

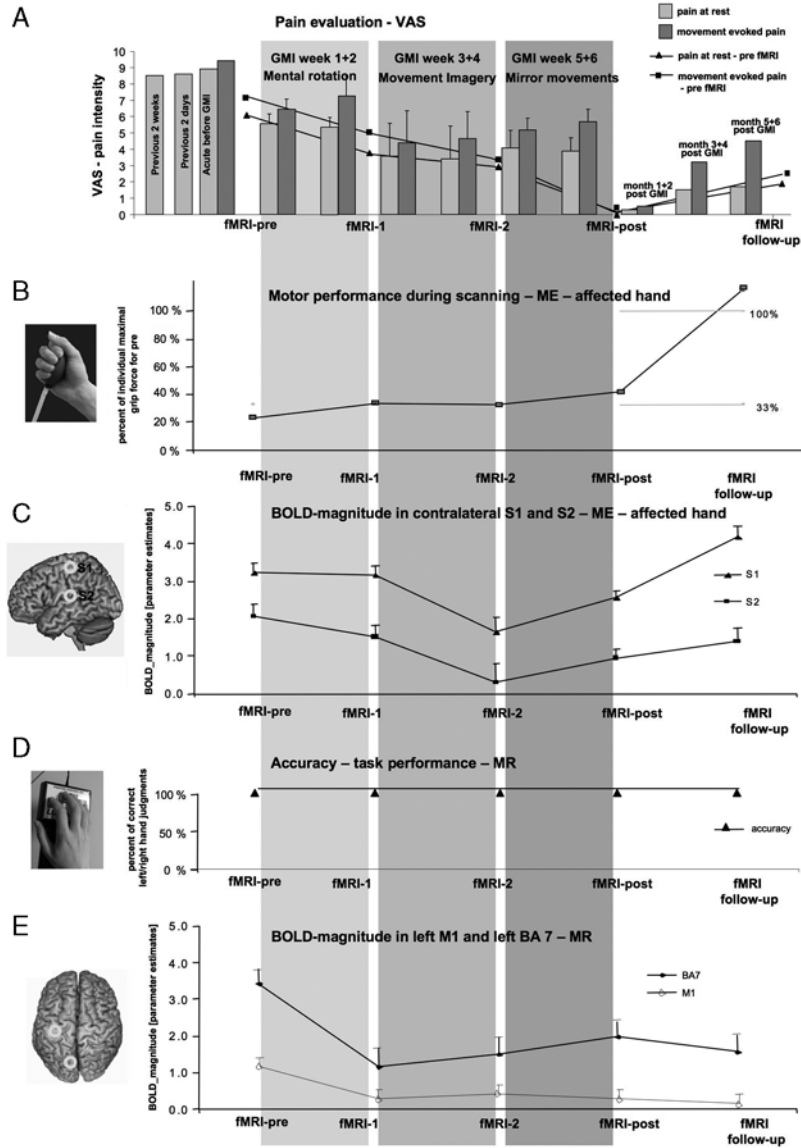
For the first 4 fMRI investigations, ME performance during fMRI was kept constant over time for both the healthy control (45, 35, 33, 32, 46% of MVC) and the patient (24, 34, 32, 42% of MVC; Fig. 1B). Whereas the healthy control had no relevant alternation in BOLD magnitude in contralateral (c)S1 (MNI coordinates:  $-39$ ;  $-24$ ;  $54$ ; activation intensity ( $\beta$ ): 1.69; 1.85; 1.86; 1.70; 1.66) and only slight variation in cS2 ( $-66$ ;  $-18$ ;  $15$ ;  $\beta$ : 1.04; 0.31; 0.58; 0.55; 0.22), the patient showed a reduction in activation in both cS1 ( $-39$ ;  $-30$ ;  $63$ ;  $\beta$ : 3.22; 3.17; 1.63; 2.56) and cS2 ( $-63$ ;  $-21$ ;  $18$ ;  $\beta$ : 2.06; 1.52; 0.31; 0.95; Fig. 1C). The activation magnitude in the anterior insula did not vary relevantly over time in the patient ( $\beta$ : 1.17; 0.48; 0.82; 0.20) or the control participant ( $\beta$ : 0.89; 0.36; 0.17; 0.47; 0.30). The ACC did not show significant activation (Supplementary Table 1, Supplemental Digital Content 2, <http://links.lww.com/CJP/A42>) and was not varying relevantly. As the ME performance of the patient was increased at the 6-month follow-up (115% of the initial maximal strength), BOLD magnitude during ME in the follow-up evaluation could not be compared with the first 4.

#### MR

The healthy participant had only slight variation in the accuracy of MR-task performance (96%, 88%, 96%, 100%, 100% correct responses). The patient performed the task each time with 100% accuracy (Fig. 1D). Both the healthy control and the patient showed activation in the superior posterior and inferior parietal lobe, the occipital lobe, the right primary motor cortex, and the right prefrontal lobe during the premeasurement. Parietal activation of the patient was the strongest in left PPC and was reduced to one third after MR training, stabilizing over time ( $-6$ ;  $-81$ ;  $48$ ;  $\beta$ : 3.43; 1.17; 1.50; 1.98; 1.57; Fig. 1E). M1 showed no significant activation during the premeasurement.

## DISCUSSION

Our case showed a good response to GMI therapy. After 6 months without further GMI, the pain intensity remained approximately 50% decreased. Therefore, the associated changes in areas representing pain during movement of the affected hand would be expected. The time course of the decrease in activation approximately paralleled pain relief for the areas associated with the discriminatory component of pain processing (S1, S2) but not for the areas associated with the affective component (ACC, anterior insula). In contrast, we did not observe relevant changes over time for the unaffected hand or for the healthy participant, which strongly implies that changes in S1 and S2 during GMI are related to the intervention and not to the nonspecific habituation effects. Our case study suggests that for movement of the affected limb, a change in activation magnitude is driven by GMI only within the areas associated with discriminative aspects of pain processing. In contrast, during the MR phase, we noticed a prominent change in the activation magnitude only in PPC,



**FIGURE 1.** Results obtained for the patient diagnosed with complex regional pain syndrome type I during the observation period of more than 6 months. The different graded motor imagery (GMI) therapy intervals are indicated with gray squares in the background of all graphs. A, Pain evaluation: intensity of at-rest and movement-evoked pain [visual analogue scale (VAS), 10 cm]. Before functional magnetic resonance imaging (fMRI)—pre—retrospective rating of pain at rest was the same as the acute pain intensity. During therapy, the patient used a pain diary with 2 measurements for pain at rest (light bars) and movement-evoked pain (dark bars) per day, averaged over each week. At follow-up, VAS values were assessed for 3 periods after GMI (months 1 and 2; months 3 and 4; months 5 and 6). In addition, we assessed the acute pain before each fMRI measurement (plotted in points connected with lines). These evaluations differed to those obtained by the pain diary, especially at the fMRI-post evaluation. B, fMRI—movement execution (ME) task: motor performance was trained before fMRI to warrant approximately 33% of the maximal grip strength. Grip strength was comparable during the first 4 fMRI measurements of the affected hand condition but differed considerably at follow-up (average more than the maximal strength during premeasurement). This indicates that fMRI maps of the follow-up measurement were not comparable to the other measurements. C, fMRI—ME task: BOLD magnitude in the contralateral primary (S1; MNI coordinates:  $-39; -30; 63$ ) and secondary (S2;  $-63; -21; 18$ ) somatosensory cortex during the first 4 fMRI measurements of the affected hand condition. The highest decrease in these contralateral areas associated with discriminative aspects of pain processing was observed after movement imagery training. After mirror training, S1 and S2 activation was increased again almost to the state after mental rotation (MR) therapy. D, fMRI—MR task: accuracy of left/right hand judgments plotted for the different times of fMRI measurement. The value was always 100% and thus the accuracy of task performance remained stable over time. E, fMRI—MR task: MR involved particularly the posterior superior parietal lobe (Brodmann area 7; coordinates:  $-6; -81; 48$ ), but showed no significant activation in the primary motor cortex (M1; plotted for the left side; coordinates:  $-39, -21, 57$ ). However, both regions were predominantly altered by the MR therapy in the first 2 weeks of GMI.

an area that processes spatial qualities of an object in the visual domain.<sup>11</sup> Other areas such as M1,<sup>12</sup> S1, S2, and visual areas did not show significant activation during the premeasurement, nor did they show reduction during therapy. A relevant contribution of M1 in the MR task has also been questioned previously.<sup>15</sup> In addition, together with the right prefrontal and bilateral cerebellar areas, the bilateral posterior parietal sulcus—a location actually entitled as part of PPC in our study and almost in the same location as the MR activation maximum in our control participant—has been described to be involved in the rubber-hand illusion.<sup>16</sup> The rubber-hand illusion experimentally induces a change in the body matrix by paired visuotactile stimulation of a rubber hand and the real hand, and, remarkably, also induces autonomic and tactile processing deficits that are characteristics of CRPS.<sup>17</sup>

This single-case design is strengthened by having a comparison participant, which controls for habituation to the testing and scanning but not for the many other aspects of an intervention that may have an effect. Our objective was not to determine the efficacy of GMI, which has already been established but to develop a design capable of exploring the cerebral correlates of those effects.

The current case raises some interesting questions: could the posterior parietal cortex hold the neural substrate of the working body matrix? Is it essentially altered after GMI and does an effect in this area account for differences in the clinical outcome of GMI in CRPS? A single-case study cannot answer these questions, but it does suggest that they are well worth asking. A randomized placebo controlled group study is necessary to further investigate these important questions.

## REFERENCES

- Birklein F, Handwerker HO. Complex regional pain syndrome: how to resolve the complexity? *Pain*. 2001;94:1–6.
- Veldman PH, Reynen HM, Arntz IE, et al. Signs and symptoms of reflex sympathetic dystrophy: prospective study of 829 patients. *Lancet*. 1993;342:1012–1016.
- Lewis JS, Kersten P, McCabe CS, et al. Body perception disturbance: a contribution to pain in complex regional pain syndrome (CRPS). *Pain*. 2007;133:111–119.
- Moseley GL. Distorted body image in complex regional pain syndrome. *Neurology*. 2005;65:773.
- Moseley GL, Gallace A, Spence C. Space-based, but not arm-based, shift in tactile processing in complex regional pain syndrome and its relationship to cooling of the affected limb. *Brain*. 2009;132:3142–3151.
- Maihofner C, Handwerker HO, Neundorfer B, et al. Patterns of cortical reorganization in complex regional pain syndrome. *Neurology*. 2003;61:1707–1715.
- Pleger B, Ragert P, Schwenkreis P, et al. Patterns of cortical reorganization parallel impaired tactile discrimination and pain intensity in complex regional pain syndrome. *Neuroimage*. 2006;32:503–510.
- Forouzanfar T, Koke AJ, van Kleef M, et al. Treatment of complex regional pain syndrome type I. *Eur J Pain*. 2002;6:105–122.
- Moseley GL. Graded motor imagery is effective for long-standing complex regional pain syndrome: a randomised controlled trial. *Pain*. 2004;108:192–198.
- Gustin SM, Schwarz A, Birbaumer N, et al. NMDA-receptor antagonist and morphine decrease CRPS-pain and cerebral pain representation. *Pain*. 2010;151:69–76.
- Kosslyn SM, DiGirolamo GJ, Thompson WL, et al. Mental rotation of objects versus hands: neural mechanisms revealed by positron emission tomography. *Psychophysiology*. 1998;35:151–161.
- Ganis G, Keenan JP, Kosslyn SM, et al. Transcranial magnetic stimulation of primary motor cortex affects mental rotation. *Cereb Cortex*. 2000;10:175–180.
- Oldfield RC. The assessment and analysis of handedness: the Edinburgh inventory. *Neuropsychologia*. 1971;9:97–113.
- Noigroup.com. *Recognise online [computer program]*. Adelaide, Australia: Noigroup.com. <http://www.noigroup.com/>. Accessed March 14, 2012.
- Sauner D, Bestmann S, Siebner HR, et al. No evidence for a substantial involvement of primary motor hand area in handedness judgements: a transcranial magnetic stimulation study. *Eur J Neurosci*. 2006;23:2215–2224.
- Ehrsson HH, Holmes NP, Passingham RE. Touching a rubber hand: feeling of body ownership is associated with activity in multisensory brain areas. *J Neurosci*. 2005;25:10564–10573.
- Moseley GL, Zalucki NM, Wiech K. Tactile discrimination, but not tactile stimulation alone, reduces chronic limb pain. *Pain*. 2008;137:600–608.